

Staphylococcal Septicemia in an Athlete

A Case Report and Review of Recent Literature

Thomas O. Clanton, MD and James E. Butler, MD*

Although skin infections are common in the athlete, there has been no report of the subsequent development of septicemia. Herein we report a case of staphylococcal septicemia that occurred in a major college football player in order to outline the etiology, clinical manifestations, diagnosis and treatment of this illness.

Case Report

J. E. S. is a 21-year-old black starting running back for the Rice Owls football team. On Thursday, Nov. 6, 1975, he awakened with severe pain in the right shoulder. He reported to the trainer who determined that his problem was in the right acromioclavicular joint where he had been hurt 6 weeks previously. He then had an x-ray which showed heterotopic ossification over the right acromioclavicular joint.

Hydrocortisone and Xylocaine® were injected into the acromioclavicular joint area. He was treated with hot packs that afternoon, but was unable to practice. On the evening of Nov. 6, he was started on Motrin® and hydrocortisone (Medrol®) with the presumptive diagnosis of acute bursitis.

Two days later he played in a regular varsity game. On Sunday morning in the training room at the regular post-game examination, he was noted to have marked induration of the right trapezius muscle with decreased tenderness over the acromioclavicular joint. He had no other complaints until the following day when he was unable to get out of bed. The trainer went to his dormitory room and

found him complaining of severe pain in the right groin with inability to move the leg or walk. He was seen by an orthopaedist who felt that he might have iliopsoas bursitis. Low-dose x-ray therapy was instituted on Monday afternoon, Nov. 11.⁵⁶

By Nov. 13, the patient had not responded to this treatment and was complaining of chills and fever, so he was admitted to the hospital for further evaluation. Vital signs on admission included blood pressure of 190/110, pulse 100, temperature 101.6° F. Physical examination revealed slightly icteric sclerae, a Grade II/VI systolic ejection murmur, pain and tenderness over the right trapezius muscle and acromioclavicular joint and pain and tenderness in the right groin along the course of the adductor tendon and over the symphysis pubis. Overnight, his temperature rose to 105° F. Initial hemogram showed hemoglobin 13.3 gm %, hematocrit 39.5%, white blood count 12,800 with a shift to the left. The SMA-12/60 showed an SGOT of 110 (normal 7-40), alkaline phosphatase 170 (normal 30-85), total bilirubin 2.7 mg % (normal, less than 1.0 mg %), and the remainder of the tests normal. A sickle cell preparation was negative as was the Australian antigen, and chest x-rays were normal.

Therapy Continues

On Nov. 14, the patient was started on penicillin 2 million units every 4 hours intravenously. On the following day admission blood cultures had grown *Staphylococcus aureus* resistant to penicillin. The patient was immediately changed from penicillin to methicillin, 2 gm intravenously every 4 hours. On Nov. 16, there was fluctuance in the area of the right acromioclavicular joint. A needle aspiration of this area under aseptic conditions

*From the Departments of Orthopaedics, The University of Texas Health Science Center, Hermann Hospital and Rice University, all of Houston, Texas.

yielded 5 ml of thick yellow pus which subsequently grew the same organism.

The patient was then taken to the operating room for incision and drainage. At the time of surgery, there was a large hole in the capsule over the acromioclavicular joint where the intraarticular sepsis had evacuated itself. Pus had dissected along the anterior border of the trapezius muscle toward the base of the neck, where a large abscess was located. Thirty milliliters of thick purulent material was evacuated. The articular cartilage in the acromioclavicular joint was absent, but the bone appeared intact. A half-inch Penrose drain was inserted into the depths of the abscess, and the wound was closed loosely. The patient showed dramatic improvement almost immediately, and studies were initiated to evaluate the aortic systolic murmur which had been present since admission. This was a systolic flow-type murmur by examination and was suspected to be benign in nature. This was substantiated when the electrocardiogram and echocardiogram were both normal, and the murmur had resolved by the end of the first week of hospitalization. Serial laboratory studies were begun along with serial x-rays. X-rays of the right shoulder and right hip showed changes consistent with septic arthritis. These x-rays are shown in Figures 1 (A-C) and 2 (A-C). The drain in the right shoulder was advanced daily and removed after 5 days. In 2 weeks, the wound had healed and there was no further drainage. The symptoms in the right adductor area gradually responded to treatment. He received a total of 4 weeks of intravenous therapy using methicillin, 2 gm intravenously every 4 hours. The patient's general condition improved, and during the last 14 days of his hospitalization he was out on pass for 3 hours a day to attend classes. On Nov. 30, the total bilirubin had returned to less than 0.5 mg % and the elevated liver enzymes gradually returned to normal over the next 2 weeks. Serial urinalyses and creatinine studies were normal.

The patient was discharged on Dec. 15, after a hospitalization of 31 days. He was discharged on cloxacillin, 500 mg q.i.d. for 1 month and has made an uneventful recovery. He participated in varsity football and track during the spring.

Etiology

Staphylococcus is an ubiquitous organism found on the skin, within the respiratory and genitourinary tracts and in the environment. Body sites can become colonized with pathogenic strains of staphylococci in carriers who may become self-infected at times of altered resistance or who may be a source of infection for others.³⁷ Active staphylococcal infections are more important in cross infection than the carrier state, but pathogenic staphylococci can be transferred in either condition by direct contact, fomites, or airborne transmission.^{37,39,70,93,113,114}

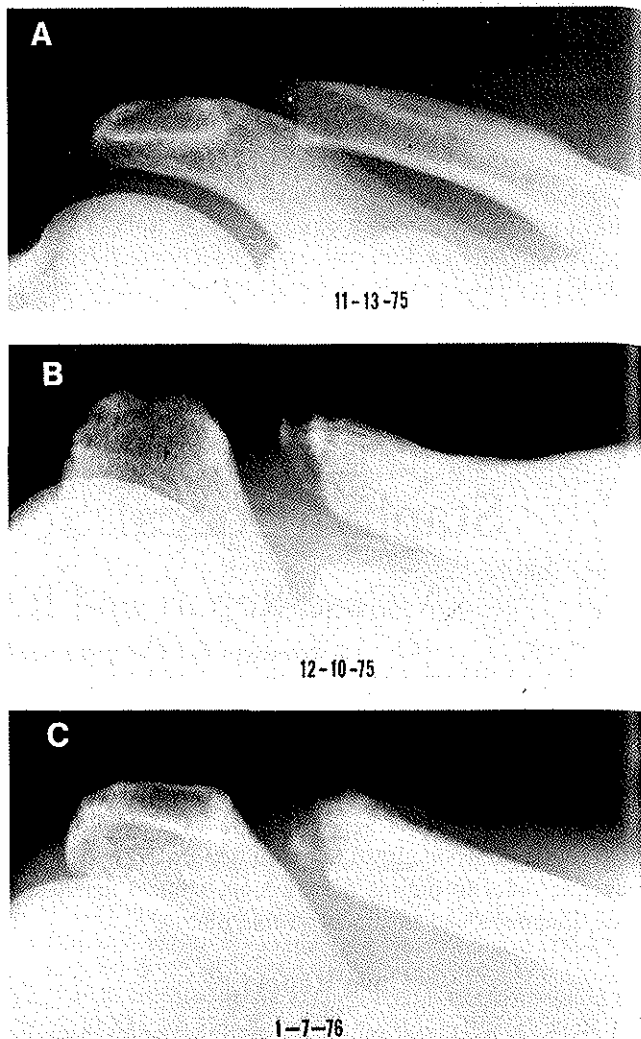


Fig 1. X-rays of the right acromioclavicular joint of the 21-year-old football player whose case is discussed by the authors. The x-rays show changes that are consistent with septic arthritis. (A) Taken on the day of admission to the hospital, eight days after the symptoms began. The heterotopic bone that is evident on the superior surface of the outer clavicle is due to an old injury. (B) One month later, three weeks after incision and drainage. (C) Two months later, asymptomatic state.

Following bacterial contamination, a state of impaired resistance must be present for infection to become established.^{24,25,92} Such alterations in host resistance may occur through the loss of skin continuity; following viral respiratory illnesses; during treatment with glucocorticoids, immunosuppressants, antimetabolites or broad-spectrum antibiotics; or in association with underlying diseases such as diabetes mellitus, alcoholism, cardiovascular insufficiency, malignancies, dysproteinemias, agranulocytosis, renal failure, ulcerative colitis or liver disease.^{1,24,25,37,39,58,86,92,106}

Obviously, many of these conditions are applicable primarily to the elderly, debilitated or more chronically ill population than to healthy athletes. However, breaks in the skin from abrasions, wounds or burns increase the sus-

ceptibility to infection, and athletes, especially football players, are subject to such injuries. Among these are "rug burns" caused by artificial turf and hand lacerations produced by equipment. These lesions may be persistently re-injured and resist healing until the season's conclusion, predisposing them to infection. Furthermore, folliculitis, furuncles, carbuncles and acne with secondary furunculosis are staphylococcal infections prevalent among younger age groups, and furunculosis is particularly common in football players and wrestlers.⁸¹

Those treating athletes must be aware that serious infections, including life-threatening septicemia, can be the consequence of superficial infections which appear to be innocent.¹¹⁹ In the case presented, the athlete had several skin lacerations and abrasions, including a particularly inflamed and suppurative lesion on the dorsal aspect of the right index finger over the proximal interphalangeal joint.

Clinical Manifestations

Following superficial infections and bacteremia, there is distant seeding of bacteria, resulting commonly in deep abscess formation, a response elicited by the specific host reaction to staphylococcus.⁹² Serious infections such as brain abscess;^{75,80,96,100,121} meningitis;^{51,100} pneumonia⁷⁰ and empyema;⁴³ osteomyelitis;^{107,118} endocarditis;^{21,59,64,69,110,111} pericarditis;^{14,34} myocardial,^{99,100,111} liver,^{16,26,95,98,99} splenic,^{99,100} adrenal,^{23,24} perinephric,¹⁰² and kidney abscesses;^{99,100} as well as septic arthritis^{46,54,68,119} may result. Therefore, presenting symptoms may be those of generalized infection, local abscess formation, or a combination of the two.

Once the full-blown picture of septicemia develops, a life-threatening situation exists. Mortality rates in the series reviewed ranged from 27% to 82%, with an average mortality rate of approximately 50%.^{1,7,24,35,53,54,58,66,68,76,86,106,111}

Fever, chills and change in mental status are usually present, together with any of the following: malaise, nausea, vomiting, symptoms from metastatic lesions or myalgia. There are generally two stages of septicemia: The first stage is characterized by high cardiac index, good response of body homeostatic mechanisms to infection and excellent prospects for complete recovery with prompt institution of appropriate therapy. The second stage is septic shock manifested by a low cardiac index, hypotension, oliguria and variable response to therapy.⁴⁰

The multiplicity of findings in septicemia makes the differentiation of signs and symptoms challenging. Mental aberrations can be secondary to the toxic state, meningitis or brain abscess formation.^{52,80,100,111} Rapid improvement with appropriate antimicrobial therapy may help distinguish the former two conditions.^{7,22,117} Jaundice can appear on the basis of a hemolytic anemia induced by the hemolysin toxins produced by the staphylococci or, more frequently, as a result of microabscesses in the liver

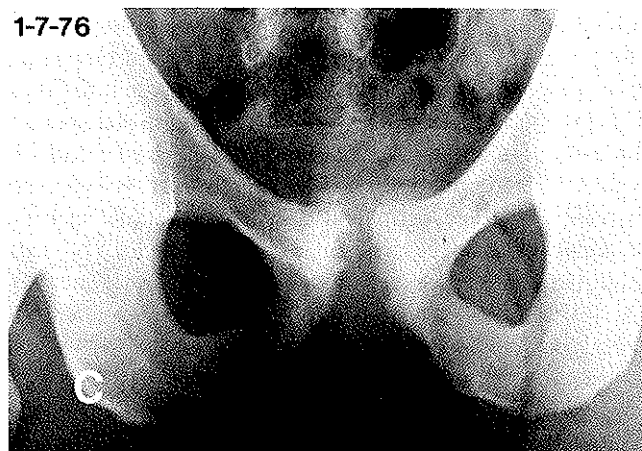
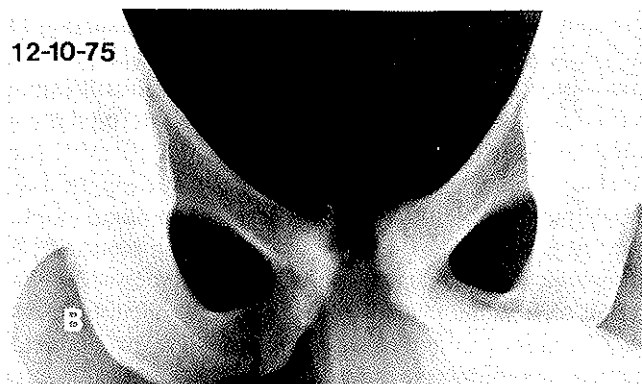
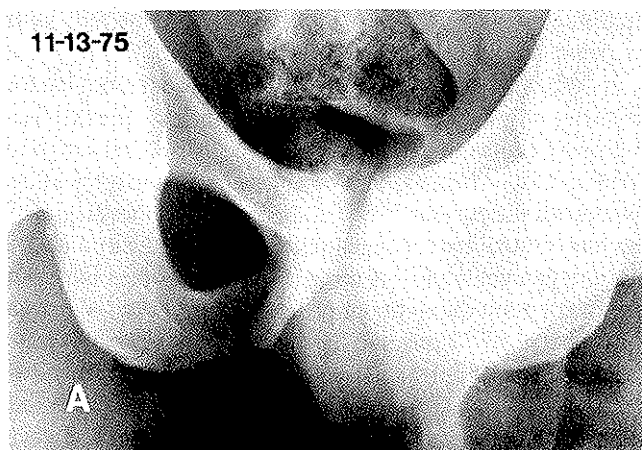


Fig 2. X-rays of the symphysis pubis of the football player discussed by the authors also show changes that are consistent with septic arthritis. (A) X-ray taken on the day of admission. (B) After three weeks of intravenous therapy. No surgery was performed. (C) Two months post onset, asymptomatic state.

with elevation of liver enzymes.^{2,26,95,99} Other considerations are congestive liver dysfunction from cardiovascular insufficiency caused by endocarditis and preexisting liver disease.^{18,99} Heart murmurs may be heard and they pose a serious diagnostic enigma, since endocarditis is a constant threat and common complication. Athletes, however, often have insignificant systolic flow murmurs, and the hypermetabolic state with increased cardiac

output can also produce or accentuate a systolic flow murmur.

In order to diagnose the presence of bacterial endocarditis, there should be a change in any preexisting murmur, a changing rhythm, multiple peripheral embolic lesions, ECG changes, and/or alterations of valve leaflets by echocardiography.^{18,29,116} Other clues to the diagnosis are the presence of congenital or valvular heart disease and the general course of the patient and his murmur with close attention paid to any signs of progressive valve dysfunction.¹¹⁷ These ancillary diagnostic clues become exceedingly important in murmurless bacterial endocarditis.^{7,73} Typical findings may be absent in a substantial number of cases, and a high index of suspicion is always warranted in the presence of bacteremia.^{69,110}

Septic arthritis with severe joint pain and limitation of range of motion is another complication that poses a major problem of differentiation for the physician treating the athlete, especially when joint pain is his presenting complaint. Attention should be directed to systemic symptoms of fever, chills, malaise and increasingly easy fatigability, as well as examining the joint for warmth, swelling, tenderness and degree of inflammation.^{61,62} Symptoms of pneumonia, which develop during staphylococcal septicemia, characteristically include pleuritic chest pain, cough productive of a creamy pink or purulent sputum, and progressive dyspnea, but these typical symptoms may be absent.^{43,70} The chest x-ray usually shows unilateral or bilateral bronchopneumonia affecting the lower lobes. Pneumatoceles are diagnostic, and empyema or pneumothorax may be seen.⁷⁰ Other occasional findings in septicemia are splenomegaly from multiple splenic abscesses and infarcts,⁹⁹ hematuria from similar kidney lesions,¹⁰⁰ abdominal masses from renal or perinephric abscesses,^{20,102} and peripheral skin manifestations such as petechial hemorrhages, pustular purpura, Osler's nodes, subcutaneous abscesses and toxic epidermal necrolysis.^{85,106,117}

Diagnosis

Once presented with any of this vast array of symptoms and clinical findings, the diagnosis of staphylococcal septicemia can only be made by the growth of the organism in cultures taken from the blood using sterile technique. Preferably, the organism will be grown in more than one, if not all, cultures obtained from more than one venipuncture site.¹⁰⁸ When possible, cultures should be taken prior to the first dose of antibiotics.^{11,106,112} Cultures may be made from the anterior nares, throat, or suspicious skin lesions; particularly from joint aspiration, Gram stain bacteria and pustular purpura which are pathognomonic skin lesions in septicemia.^{37,85} A swollen, inflamed joint should be aspirated early under strictly sterile conditions and the aspirant sent for Gram stain, culture and sensitivity studies.^{61,62} Since the results of cultures are not generally available for 24 hours, there has been a search for more

rapid means of detecting bacteremia. A method of radio-metric detection of bacterial growth using Carbon-14-labeled glucose has been described with the results available as early as 6 hours.^{17,27,28,88,89,101,109,119}

The nitroblue tetrazolium test has been performed using blood and synovial fluid with the findings of increased numbers of positive-staining cells in cases of septic arthritis, septicemia and other infectious conditions.^{47,49,74,77,83,120} This test was positive in all of 29 cases of bacteremia in one study, and results were known within the hour.⁷⁴ Gas chromatography,⁷⁹ light-scattering techniques,⁶⁵ and impedance measurements¹⁰⁴ are other experimental methods under investigation for rapid detection of bacteremia. Nonetheless, blood cultures remain the keystone to the diagnosis of septicemia and must be performed whenever this is suspected.

Treatment

Treatment centers around the proper diagnosis with microbiologic studies. In septicemia, prompt institution of the appropriate antimicrobial agent is mandatory to prevent a disastrous outcome.⁶⁷ Consequently, empirical therapy should begin with a penicillinase-resistant antibiotic such as nafcillin, oxacillin, methicillin or cephalothin.^{32,39,119} The antibiotic is administered parenterally prior to the results of blood cultures based upon the clinical picture and Gram stain of any material aspirated from an inflamed joint or skin lesion.^{115,119} Culture results are generally available within 24 hours, and sensitivities plus penicillinase production tests by 48 hours. Serum bacteriocidal levels should be done on all patients when possible. Patients with septicemia require at least 4 weeks of parenteral antibiotics and should be discharged on cloxicillin, dicloxicillin or a cephalosporin for an additional month.^{32,61,115,119} It could become necessary to alter therapy once bacteriologic and in vitro susceptibility data become available. The physician should be aware of the rare staphylococci that are methicillin-resistant and that may be resistant to multiple antibiotics.^{9,12,32,55,60} In such cases, vancomycin is the drug of choice.^{12,32,48,66,105,115,119}

The use of the semisynthetic penicillins has resulted in a reduced mortality rate from serious staphylococcal infections;³ but complications of therapy include hypersensitivity reactions, superinfection or methicillin nephritis characterized by oliguria, azotemia, hematuria (microscopic or gross) and eosinophilia.^{8,15,32,45,57,115} Phlebitis is common with intravenous administration of cephalothin, nafcillin and vancomycin, and the latter can also cause renal damage and deafness.^{32,48,105}

In cases where there is deep abscess formation, surgical intervention is often necessary. The reason for this is that large abscesses contain phagocytized bacteria in neutrophils of low metabolic activity. These bacteria are not susceptible to bacteriocidal agents, even though they

penetrate the abscess cavity and bacteriocidal concentrations are reached.^{82,84,87,92} The stage of the infection, the size of the abscess and its accessibility are the determinants of the most effective means of surgical intervention. When the infection is located superficially, there are several alternatives. Many furuncles and carbuncles will "point" and spontaneously discharge their contents without further consequences or need for other treatment. Hot compresses are often helpful and local skin cleansing cannot be over-emphasized.⁸¹ In severe cases, needle aspiration or surgical incision and drainage may be necessary for rapid, safe resolution of these skin lesions. Surgical therapy is unnecessary for the majority of liver, kidney and splenic abscesses, since microabscesses are the predominant pathology in these organs,^{16,19,90,91,95,98,99,100} and these usually will resolve during prolonged antibiotic therapy. Nevertheless, pyogenic abscesses may be solitary, multiple or multilocular, and drainage is essential for selected solitary or large multiple lesions. Perinephric abscesses should be considered along with renal abscesses in septicemic patients who complain of unilateral pain in the renal area and definite localized tenderness at the costo-vertebral angle, since these lesions lend themselves well to surgical evacuation.^{20,102} Cases of empyema can be treated by thoracentesis, closed drainage using chest tubes, or open thoracostomy and drainage.^{5,42,43,71,97} Brain abscesses are another complication of septicemia in which surgical treatment assumes major importance.^{75,80,96} During the acute process, the patient should receive appropriate antibiotics, antiinflammatory agents such as steroids and closely monitored fluid therapy.

The abscess will begin to wall off after 10 days, allowing localization and drainage.⁸⁰ This is accomplished by intermittent aspiration, constant drainage or excision of the abscess, with only fair results in the majority of cases.^{63,75,80,96,121} Septic arthritis is yet another complication in which prompt surgical intervention is paramount. Location is a deciding factor in one's approach, since easily accessible joints such as the acromioclavicular, glenohumeral, knee and elbow joints may be adequately treated by aspiration, whereas the hip and sacroiliac joints are often difficult to aspirate repeatedly and may require open drainage.^{46,61} The use of closed-suction irrigation systems has been discussed previously and may be an effective tool in the treatment of septic joints.^{4,30,31,61} Clinical judgment is crucial in determining which patients with septicemia require more than just the routine course of antibiotics and aspiration of abscesses.

Patients who are well treated and survive staphylococcal septicemia rarely have late complications.¹¹⁷ However, persistent fever and leukocytosis despite adequate serum antimicrobial activity suggest an undrained, deep abscess or superinfection.^{7,87} Unsuspected deep abscesses may be detected using gallium-67 scanning.^{6,13,72} Rarer postsepsis syndromes include febrile pleuropericarditis,⁷⁸ periureteritis plastica,¹⁰ and acute dif-

fuse glomerulonephritis.^{41,103} Weight loss and weakness are seen in the recovery phase, and athletes must be brought back slowly to competitive levels.

Conclusion

We have presented a case of staphylococcal septicemia occurring in a major college football player who recovered and returned to competition following surgical drainage of an abscess and appropriate antibiotic therapy. Selective aspects of etiology, clinical manifestations, diagnosis and management are presented for those who may encounter this serious infection.

References

- Allen JD, Roberts CE Jr, Kirby WMH: Staphylococcal Septicemia treated with methicillin: Report of 21 cases. *N Eng J Med* 226:11-116, 1962
- Altmeier WA, Schowengerdt CG, Whiteley DH: Abscesses of the liver: Surgical considerations. *Arch Surg* 101:258-266, 1970
- Altmeier WA, Todd JC, Inge WW: Newer aspects of Septicemia in surgical patients. *Arch Surg* 92:556-572, 1966
- Anderson LD, Horn LG: Irrigation-suction technic in the treatment of acute hematogenous osteomyelitis, chronic osteomyelitis and acute chronic joint infections. *South Med J* 63:745-754, 1970
- Andrews NC: The surgical treatment of chronic empyema. *Dis Chest* 47:533-538, 1965
- Anghileri LJ: 67 Ga-citrate accumulation by staphylococcal abscesses and by tumors. A common cause: Changes in the alkaline-earth's metabolism. *Nucl Med (Stuttg)* 13:151-159, 1974
- Austin TW, Wallace JF: Staphylococcal septicemia: a critical review of its treatment and association with infective endocarditis. *Infection* 1:214-217, 1973
- Baldwin DS, Levine BB, McCluskey RT, Gallo, GR: Renal failure and interstitial nephritis due to penicillin and methicillin. *N Engl J Med* 279:1245-1252, 1968
- Barrett FF, McGehee RF Jr, Finland M: Methicillin-resistant staphylococcus aureus at Boston City Hospital. Bacteriologic and epidemiologic observations. *N Engl J Med* 279:441-448, 1968
- Behrens MM, Holland JM: Periureteritis plastica: Report of a case following staphylococcal infections. *J Urol* 97:829-832, 1967
- Belli J, Waisbren BA: The number of blood cultures necessary to diagnose most cases of bacterial endocarditis. *Am J Med Sci* 232:284-288, 1956
- Benner EJ, Morthland V: Methicillin-resistant staphylococcus aureus. *N Engl J Med* 277:678-680, 1967
- Blair DC, Carroll M, Carr EA, Fekety FR: 67 Ga-citrate for scanning experimental staphylococcal abscess. *J Nucl Med* 14:99-102, 1973
- Boyle JD, Pearce ML, Guze LB: Purulent pericarditis: Review of literature and report of eleven cases. *Medicine* 40:119-144, 1961
- Brauninger GE, Remington JS: Nephropathy associated with methicillin therapy. *JAMA* 203:103-105, 1968
- Brodine WN, Schwartz SI: Pyogenic hepatic abscesses: Review of representative literature and presentation of ten cases. *NY State J Med* 73:1657-1661, 1973
- Brooks K, Sodeman T: Rapid detection of bacteremia by a

- radiometric system. A clinical evaluation. *Am J Clin Path* 61:859-866, 1974
18. Bruno MS, Ober WB (eds): Clinicopathologic Conference. Jaundice and coma in heroin addiction. *NY State J Med* 73:303-312, 1973
 19. Carroll G: Nontuberculous infections of the urinary tract, Campbell MF, Harrison TH (eds): *Urology*, ed 3. Philadelphia, W. B. Saunders Co, 1970, Vol 1, pp 402, 406, 409, 434
 20. Carroll G: Nontuberculous infections of the urinary tract, Campbell MF, Harrison TH (eds): *Urology*, ed 3. Philadelphia, W. B. Saunders Co, 1970, Vol 1, pp 433-435
 21. Chase RM Jr: Infective endocarditis today. *Med Clin North Am* 57:1383-1393, 1973
 22. Clinicopathologic Conference. A case of staphylococcal septicaemia with endocarditis and cerebral abscess. Demonstrated at the Royal Postgraduate Medical School. *Br Med J* 1:479-482, 1967
 23. Cluff LE: Localization of staphylococcal infection. *Contrib Microbiol Immunol* 1:595-599, 1973
 24. Cluff LE, Reynolds RC, Page DL, Breckenridge JL: Staphylococcal bacteremia and altered host resistance. *Ann Intern Med* 69:859-873, 1968
 25. Cluff LE, Reynolds RC, Page DL, Breckenridge JL: Staphylococcal bacteremia: Demographic, clinical and microbiological features of 185 cases. *Trans Am Clin Climatol Assn* 79:205-215, 1968
 26. DeBakey ME, Jordan GE Jr: Surgery of the Liver, in Schiff L (ed): *Diseases of the Liver* ed 4. Philadelphia, J. B. Lippincott, 1975, pp 1103-1119
 27. De Land F, Wagner HN Jr: Automated radiometric detection of bacterial growth in blood cultures. *J Lab Clin Med* 75:529-534, 1970
 28. De Land F, Wagner HN Jr: Early detection of bacterial growth with Carbon-14-labeled glucose. *Radiology* 92: 154-155, 1969
 29. Dillon JC, Feigenbaum H, Konecke LL, Davis RH, Chang S: Echocardiographic manifestations of valvular vegetations. *Am Heart J* 86:698-704, 1973
 30. Dilmaghani A, Close JR, Rhineland FW: A method for closed irrigation and suction therapy in deep wound infections. *J Bone Joint Surg* 51-A:323-342, 1969
 31. Dombrowski ET, Dunn AW: Treatment of osteomyelitis by debridement and closed wound irrigation-suction. *Clin Orthop* 43:215-231, 1965
 32. Drugs for staphylococcal infections. *Med Let Drugs Ther* Vol 15, No 23, Nov 9, 1973
 33. Ehrenkranz NJ: Person-to-person transmission of staphylococcus aureus: Quantitative characterization of nasal carrier spreading infection. *New Engl J Med* 271:225-230, 1964
 34. Ehrlich DA, Widmann JJ, Abdmann WH: Acute effusive-constrictive Staphylococcal pericarditis. *Chest* 67:721-723, 1975
 35. Epstein EH, Flynn P, Davis RS: Adult toxic epidermal necrolysis with fatal Staphylococcal septicemia. *JAMA* 229:425-427, 1974
 36. Farhoudi HO, Mody VR: Staphylococcal bacteremia in heroin addicts. *Med Ann DC* 39:187-194, 1970
 37. Feket FR Jr: The epidemiology and prevention of Staphylococcal infections. *Medicine* 43:593-613, 1964
 38. Felman AH, Shulman ST: Staphylococcal osteomyelitis, sepsis and pulmonary disease. *Radiology* 117:649-655, 1975
 39. Finland M: Staphylococcal infections in antistaphylococcal antibiotics. *Med Times* 93:101-114, 1965
 40. Fischer MJ, McArtor RE: Staphylococcal Septicemia. A study of 100 cases. *Oh Med J* 63:1325-1327, 1967
 41. Freeman BC, Kreps EM, Ronsheim NJ, Lejano RF, Sommers SC: Poststaphylococcal glomerulonephritis in heroin addicts. *NY State J Med* 74:2241-2243, 1974
 42. Gautam HP: Non-operative treatment of staphylococcal empyema thoracic in children. *Indian J Pediat* 40:361-364, 1973
 43. Geley L, Hartl H: Pleuro-pulmonary suppuration in neonates and infants. *Prog Pediat Surg* 4:29-61, 1972
 44. Geraci JE: Antibiotic therapy of bacterial endocarditis. *Med Clin North A* 42:1101-1140, 1958
 45. Gilbert DN, Sanford JP: Methicillin: Critical appraisal after a decade of experience. *Med Clin North Am* 54:1113-1125, 1970
 46. Goldenberg GL, Brandt KD, Cohen S, Cathcart ES: Treatment of septic arthritis: Comparison of needle aspiration and surgery as initial modes of joint drainage. *Arthritis Rheum* 18:83-90, 1975
 47. Gordon AM, Rowan RM, Brown T, Carson HG: Routine application of the nitroblue tetrazolium test in the clinical laboratory. *J Clin Path* 26:52-56, 1973
 48. Graham RC: Antibiotics for treatment of infections caused by Gram-positive cocci. *Med Clin North Am* 58:505-517, 1974
 49. Gupta RC, Steigerwald JC: Nitroblue tetrazolium test in the diagnosis of pyogenic arthritis. *Ann Int Med* 80:723-726, 1974
 50. Hall WJ, III: Septicemia Revisited, 1965-1966. *J Maine Med Assn* 62:91-100, 1971
 51. Hambleton G, Davies PA: Diagnosis and management of bacterial meningitis. *Drugs* 8:15-53, 1974
 52. Harrison MJG, Hampton JR: Neurological presentation of bacterial endocarditis. *British Med J* 2:148-151, 1967
 53. Hassall JE, Rountree PM: Staphylococcal septicaemia. *Lancet* 1:213-217, 1959
 54. Hay DR: Staphylococcal septicaemia and pyaemia. *Quart J Med* 29:313-331, 1960
 55. Hone R, Keane CT: A clinical study of infections caused by methicillin-resistant Staphylococcus aureus. *Infection* 2:213-217, 1974
 56. Hucherson DC, Freeman GE Jr: Iliopsoas bursitis. A cause of hip pain frequently unrecognized. *Am J Orthop* 4:220, 1962
 57. Jensen HA, Halveg AB, Saunamaki KI: Permanent impairment of renal function after methicillin nephropathy. *British Med J* 4:406, 1971
 58. Jessen O, Rosendal K, Bulow P, Faber V, Eriksen KR: Changing Staphylococci and Staphylococcal infections. A ten-year study of bacteria and cases of bacteremia. *New Engl J Med* 281:627-635, 1969
 59. Kaye D: Changes in the spectrum, diagnosis and management of bacterial and fungal endocarditis. *Med Clin North Am* 57:941-957, 1973
 60. Kayser FH: Methicillin-resistant Staphylococci: 1965-1975. *Lancet* 2:650-653, 1975
 61. Kelly PJ: Bacterial arthritis in the adult. *Orthop Clin North Am* 6:973-981, 1975
 62. Kelly PJ, Martin WJ, Coventry MB: Bacterial (Suppurative) arthritis in the adult. *J Bone Joint Surg* 52A:1595-1602, 1970
 63. Kerr FWL, King RB, Meagher JN: Brain abscess: A study of forty-seven consecutive cases. *J Am Med Assn* 168:868-872, 1958
 64. Kahn MY, Hall WH, Gerding DN: Staphylococcal endocarditis in narcotic addicts. *Minn Med* 58:244-247, 1975
 65. Khan W, Conroni G, Wyatt PJ, Ross S: Rapid detection of bacteria and antibiotic sensitivity in body fluids by differential light scattering. Abstracts of the Annual Meeting of the American Society for Microbiology, p 87, 1972
 66. Kirby WMM, Perry DM, Bauer AW: Treatment of Staphylococcal septicemia with vanomycin: Report of 33 cases. *New Engl J Med* 262:49-55, 1960

67. Koenig MG: The treatment of Staphylococcal infections. *Med Clin North Am* 47:1231-1245, 1963
68. Kucers A, Bennett NM: Staphylococcal septicaemia. *Med J Australia* 1:217-222, 1964
69. LeFrock JL, Klainer AS: Bacterial endocarditis. *W Virg Med J* 71:1-7, 1975
70. Lerner AM, Jankauskas K: The classic bacterial pneumonias. *Disease-a-month*, pp 1-46, Feb 1975
71. LeRoux BT: Empyema thoracis. *Brit J Surg* 52:89-99, 1965
72. Littenberg RL, Taketa RM, Alazrak NP, Halpern SE, Ashbur WL: Gallium-67 for localization of septic lesions. *Ann Int Med* 79:403-406, 1973
73. MacGregor GA: Murmurless bacterial endocarditis. *Brit Med J* 1:1011-1013, 1956
74. Matula G, Paterson PY: Spontaneous in vitro reduction of nitroblue tetrazolium by neutrophils of adult patients with bacterial infection. *New Engl J Med* 285:311-317, 1971
75. Meloff P: Intracranial abscess. *Minn Med* 55:357-361, 1972
76. Merrill SL, Davis A, Smolens B, Finegold SM: Cephalothin in serious bacterial infection. *Ann Int Med* 64:1-12, 1966
77. Merzbach D, Obedeau N: Standardization of the nitroblue-tetrazolium test. *J Med Microbiol* 8:375-384, 1975
78. Miller GC, Witham AC: Delayed febrile pleuropericarditis after sepsis. A possible analogue of the postcardiotomy syndrome. *Ann Int Med* 79:194-197, 1973
79. Mitruka BM, Jonas AM: Rapid identification of bacteria in cultures of blood and body fluids by gas chromatography. Abstracts of the Annual Meeting of the American Society for Microbiology, p 87, 1972
80. Moore GA, Murray TL: Infections including abscesses of the brain, spinal cord, intraspinal and intracranial regions. *Surg Ann* 6:413-437, 1974
81. Moschella SL, Pillsburg DM, Hurley HJ Jr: *Dermatology*, Vol 1. Philadelphia, W. B. Saunders Co., 1975, pp 502-504
82. Nelson JD: Antibiotic concentrations in septic joint effusions. *New Engl J Med* 284:349-353, 1971
83. Park BH, Fikrig SM, Smithwick EM: Infection and nitroblue-tetrazolium reduction by neutrophils. A diagnostic aid. *Lancet* 2: 532-534, 1968
84. Parker RH, Schmid FR: Antibacterial activity of synovial fluid during therapy of septic arthritis. *Arthritis Rheum* 14:96-104, 1971
85. Plaut ME: Staphylococcal septicemia and pustular purpura. Report of cases. *Arch Dermatol* 99:82-85, 1969
86. Powell DEB: Staphylococcal septicaemia in a general hospital. *Brit Med J* 2:336-339, 1961
87. Quie PG, Hill HR, Davis AT: Defective phagocytosis of Staphylococci. *Ann NY Acad Sci* 236:233-243, 1974
88. Randall EL: Comparison of a radiometric method with conventional cultural methods for detection of bacteremia. Abstracts of the Annual Meeting of the American Society for Microbiology, p 87, 1972
89. Renner ED, Gatheridge LA, Washington JA II: Evaluation of radiometric system for detecting bacteremia. *Appl Microbiol* 26:368-372, 1973
90. Robbins SL: *Pathologic Basis of Disease*, p 1015. Philadelphia, W. B. Saunders Co., 1974
91. Robbins SL: *Pathologic Basis of Disease*, Philadelphia, W. B. Saunders Co., 1974, pp 119-120
92. Rogers DE: Observations on the nature of Staphylococcal infections. *Bull NY Acad Med* 35:25-38, 1959
93. Roodyn L: Epidemiology of Staphylococcal infections. *J Hygiene* 58:1-10, 1960
94. Rothwell-Jackson RL, Zeegen R, Cripps CM: Staphylococcal septicemia complicating intravenous therapy. *Brit J Clin Pract* 22:482-485, 1968
95. Rubin RH, Swartz MN, Malt R: Hepatic abscess: Changes in clinical, bacteriologic and therapeutic aspects. *Am J Med* 57:601-610, 1974
96. Samson DS, Clark K: A current review of brain abscess. *Am J Med* 54:201-210, 1973
97. Samson PC: Empyema thoracis: Essentials of present-day management. *Ann Thorac Surg* 11:210-221, 1971
98. Schwartz SI: *Surgical diseases of the liver*, New York, McGraw-Hill Book Co., 1964, p 100
99. Scully RF, Galdabini JJ, McNeely BU (eds): Case records of the Massachusetts General Hospital: Weekly Clinicopathologic Exercises. Case No. 30, 1975. *New Eng J Med* 293:247-253, 1975
100. Scully RF, McNeely BU (eds): Case records of the Massachusetts General Hospital: Weekly Clinicopathologic Exercises. Case No. 5, 1975. *New Eng J Med* 292:255-260, 1975
101. Thiemke WA, Wicher K: Laboratory experience with a radiometric method for detecting bacteremia. *J Clin Microbiol* 1:302-308, 1975
102. Thorley JD, Jones SR, Sanford JP: Perinephric abscess. *Medicine* 40:441-451, 1974
103. Tu WH, Shearn MA, Lee JC: Acute diffuse glomerulonephritis in acute Staphylococcal endocarditis. *Ann Int Med* 71:335-341, 1969
104. UR A, Brown DFJ: Rapid detection of bacterial activity using impedance measurements. *Biomed engineering* 9:18-20, 1974
105. Vacek V: Clinical value of antistaphylococcal drugs. *Contrib Microbiol Immunol* 1:624-633, 1973
106. Waisbren BA, Abboud F: Bacteremia due to coagulase-positive Staphylococcus aureus. *Ann Int Med* 52:643-667, 1960
107. Waldvogel FA, Medoff G, Schwartz MN: Osteomyelitis: A review of clinical features, therapeutic considerations and unusual aspects. *New Eng J Med* 282:198-206, 316-321, 1970
108. Washington JA II: Blood cultures: Principles and techniques. *Mayo Clin Proc* 50:91-98, 1975
109. Waters JR, Swarun AA: Developments in the radiometric detection of bacteremia using Bactec. Abstracts of the Annual Meeting of the American Society for Microbiology, p 87, 1972
110. Weinstein L, Rubin RH: Infective endocarditis, 1973. *Prog Cardiovasc Diseases* 16:239-274, 1973
111. Weinstein L, Schlesinger JJ: Pathoanatomic, pathophysiologic and clinical correlations in endocarditis. *New Eng J Med* 291:832-836, 1122-1126, 1974
112. Werner AS, Cobbs CG, Kaye D, Hook EW: Studies on the bacteremia of bacterial endocarditis. *JAMA* 202: 199-203, 1967
113. White A, Smith J, Varga DT: Dissemination of Staphylococci. *Arch Int Med* 114:651-656, 1964
114. White A, Smith J, Varga DT: Dissemination of Staphylococci. *Arch Int Med* 114:651-656, 1964
115. Wilkowske CJ, Hermans PE: Actions and uses of antimicrobial agents in the treatment of musculoskeletal infections. *Orthop Clin North Am* 6:1129-1144, 1975
116. Wilson DA: Diagnostic ultrasound. *New Physician* 24:48-51, Dec 1975
117. Wilson R, Hamburger M: Fifteen years' experience with Staphylococcus septicemia in a large city hospital. Analysis of forty-five cases in the Cincinnati General Hospital 1940 to 1954. *Am J Med* 22:437-457, 1957
118. Winsters JL, Cahen I: Acute hematogenous osteomyelitis: A review of sixty-six cases. *J Bone Joint Surg* 42A:691-704, June 1960
119. Wise RI: Modern management of severe Staphylococcal disease. *Medicine* 52:295-304, 1973
120. Wollman MR, Brenna BL, Stenzel KH, David DS, Lewy JE, Rubin AL, Miller DR: The nitroblue tetrazolium test. Usefulness in detecting bacterial infections in uraemic and immunosuppressed renal transplant patients. *Lancet* 2:289-291, 1972
121. Yoshikawa TT, Goodman SJ: Brain Abscess-Teaching Conference, University of California, Los Angeles and Harbor General Hospital, Torrance (Specialty Conference), *Western J Med* 121:207-219, 1974