

Comparison of Chevron Osteotomy and Modified McBride Bunionectomy for Correction of Mild to Moderate Hallux Valgus Deformity

Jeffrey E. Johnson, M.D.,* Thomas O. Clanton, M.D.,† Donald E. Baxter, M.D.,† and Mark S. Gottlieb, Ph.D.*
Milwaukee, Wisconsin and Houston, Texas

ABSTRACT

The purpose of this study was to compare the results of the Chevron osteotomy to the DuVries' modification of the McBride procedure using identical criteria in two groups of patients. Thirty-two patients (48 feet) that had a Chevron osteotomy and 10 patients (17 feet) who had a modified McBride bunionectomy without metatarsal osteotomy for treatment of mild to moderate hallux valgus were retrospectively reviewed using subjective and objective criteria. Both groups were matched according to age, severity of deformity, and length of follow-up. Ninety-two percent of patients in the Chevron group and 88% of patients in the McBride group responded that they were either totally satisfied or improved regarding pain relief and appearance of the foot following surgery. Chevron osteotomy resulted in a statistically significant greater correction of the intermetatarsal 1-2 angle than did the McBride bunionectomy. Postoperative metatarsophalangeal joint range of motion was not significantly different for the two groups. Following Chevron osteotomy, five (10%) metatarsal heads exhibited radiographic changes of cyst formation and/or increased osteodensity and three (6%) of the osteotomies healed in a malunited position. One of the three metatarsal head malunions occurred in a patient that also had a lateral capsular release, however, none of the five cases that developed radiographic changes in the first metatarsal head was associated with a lateral capsular release. Lateral capsular release with the Chevron osteotomy did not improve the amount of correction of the hallux valgus deformity and it may be a contributing factor to instability at the osteotomy site leading to a valgus malunion.

INTRODUCTION

Chevron osteotomy of the first metatarsal and the modified McBride bunionectomy are two widely ac-

cepted procedures for treatment of adult hallux valgus. For the mild to moderate deformity, excellent results have been reported using both procedures. Therefore, the choice of technique has largely been based on the surgeon's personal preference, training, and the community standards.

The purpose of this study was to compare the results of the Chevron osteotomy to the DuVries' modification of the McBride procedure using identical criteria in two groups matched according to their age and severity of deformity.

MATERIAL AND METHODS

Ninety patients that underwent a Chevron osteotomy and 18 patients that underwent a DuVries' modification of the McBride procedure without a proximal metatarsal osteotomy were identified for retrospective review. All patients underwent primary bunionectomy by one of the senior authors (T.O.C. and D.E.B.) during the years 1983 through 1986. Additional criteria for inclusion in the study group were: between 20 and 55 years of age, preoperative intermetatarsal (IM) 1-2 angle of less than or equal to 15°; no prior involvement of the hallux by surgery, osteoarthritis, or inflammatory arthritis; and a minimum follow-up of 1 year. A review of charts and radiographs combined with a physical examination or personal telephone interview formed the data base for this study.

Surgical Technique

The Chevron osteotomy procedure was performed as described by Corless and others^{3,8} except that a single 0.045 inch smooth pin was driven percutaneously dorsally to plantarward to fix the distal metatarsal osteotomy. In a few patients where complete correction of the hallux valgus deformity by osteotomy alone was not obtained, a lateral capsulotomy and adductor tenotomy were added. The tenotomy was usually performed by reaching across the distracted metatarsophalangeal (MTP) joints with a small scalpel

* The Medical College of Wisconsin, Milwaukee, Wisconsin.

† University of Texas Health Science Center, Houston, Texas.

Address reprint requests to Jeffrey E. Johnson, M.D., Department of Orthopaedic Surgery, Medical College of Wisconsin, 8700 West Wisconsin Avenue, Milwaukee, Wisconsin 53226.

blade through the medial incision to incise the lateral joint capsule vertically and divide the conjoined adductor tendon. Early in the series a separate dorsal first web space incision was used for the capsulotomy and tenotomy.

The longitudinal medial capsular incision was imbricated with absorbable sutures to hold the toe in a corrected position. The skin was closed with interrupted silk sutures. Ambulation as tolerated in a postoperative sandal was allowed the day of surgery. Gauze wrap dressings were changed at weekly intervals of 2 weeks, the pin was then removed and an elastic bandage held the toe in the corrected position. At 4 weeks from surgery, gradual resumption of footwear was begun.

The DuVries' modification of the McBride procedure⁴ was performed as described by Mann without fibular sesamoidectomy or proximal metatarsal osteotomy.^{11,12} The incisions were closed with interrupted nylon sutures. Ambulation as tolerated in a postoperative sandal was allowed the day of surgery. Gauze wrap dressings reinforced with half-inch adhesive tape were reapplied at weekly intervals until 6 weeks from surgery when gradual resumption of footwear was begun. All patients in both groups were encouraged to begin passive and active range of motion exercises of the toes following the period of dressing immobilization.

Measurements of pre- and postoperative IM 1-2 angle, metatarsophalangeal-1 angle, relative length of first and second metatarsals, tibial sesamoid position, and first MTP subluxation was performed according to the American Orthopaedic Foot and Ankle Society guidelines.¹⁵

Standing radiographs were available for 50% of the Chevron and 40% of the McBride patients. The axis of the first metatarsal was measured in both groups along a line connecting the center of the metatarsal head to the center of the metatarsal base. Other methods of MTP-1-angle measurement underestimate the amount of correction obtained by a distal metatarsal osteotomy.¹⁵ Subjective results were recorded on a questionnaire that asked patients about overall satisfaction, cosmesis, toe mobility, footwear restriction, length of postoperative disability, and whether they would consider having the procedure again,

EVALUATION OF RESULTS

Chevron Group

Of the 90 patients that underwent Chevron osteotomy, 32 patients (48 feet) were available for review. All patients returned for an interview and postoperative X-rays. All but two patients had a physical examination at followup. There were 29 females and 3 males with

an average age of 43.5 years (range, 27-54 years). The mean duration of followup was 25 months (range, 15, 39 months).

Modified McBride Group

Of the 18 patients that underwent a modified McBride bunionectomy, 10 patients (17 feet) were available for review. All 10 patients returned for an interview, physical examination and had pre- and postoperative X-rays. All patients were females with an average age of 35.4 years (range, 23-50 years). The mean duration of followup was 37.9 months (range, 16-59 months).

Additional Procedures

Twenty-two of the 32 patients (69%) in the Chevron osteotomy group and seven of the 10 patients (70%) in the modified McBride group underwent additional forefoot procedures at the time of hallux valgus correction (Table 1). Fifty-four procedures were performed in the Chevron group for an average of 1.1 procedures per foot. Eleven additional procedures were performed in the modified McBride group for an average of 0.6 additional procedures per foot.

SUBJECTIVE RESULTS

No statistically significant differences were found between the Chevron and modified McBride patients using any of the subjective criteria below.

Pain Relief

Following Chevron osteotomy, total satisfaction in regard to pain relief was achieved in 36 of 48 feet (75%), improved in eight (17%), the same in one (2%), and worse in four (6%).

Following the modified McBride procedure, 12 out of 17 feet (70%) were totally satisfactory, three (18%) were improved and two (12%) were the same regarding

TABLE 1
Additional Forefoot Procedures

	Chevron (N = 22)	Modified McBride (N = 8)
Hammertoe correction	24	1
Bunionette correction	12	4
Interdigital neuroma excision	7	1
Partial toenail and matrix excision	4	—
Lesser metatarsal osteotomy	2	1
Exostectomy hallux IP joint	3	1
Exostectomy first metatarsal shaft	—	2
Excision dorsal spur first MTP joint	1	—
Excision ganglion	1	1
Total	54	11
Additional procedures per foot	1.1	0.6

IP = interphalangeal, MTP = metatarsophalangeal.

pain relief. No patients in this group felt he/she had more pain postoperatively.

Cosmetic Results

Following Chevron osteotomy, complete satisfaction with appearance of the foot was achieved in 37 feet (77%). Eight feet (17%) were improved, one (2%) appeared the same, and two (4%) were felt to be worse. In the eight feet that were only improved, four feet had initially satisfactory great toe alignment which was subsequently lost, and in four feet the great toe was never corrected to the patient's satisfaction.

Following modified McBride bunionectomy, complete satisfaction with appearance of great toe alignment was achieved in 11 feet (65%) and the remaining six feet (35%) were felt to be improved. No feet were judged to appear the same or worse following modified McBride procedure. Of the six that were improved, three feet initially had satisfactory alignment that was subsequently lost, and three feet had a residual prominent medial eminence on the head of the first metatarsal.

Metatarsophalangeal Joint Mobility

In the Chevron group, no MTP joint stiffness was noted by the patient in 28 feet (58%), noticeable stiffness that was not bothersome was reported for 18 feet (38%) and two feet (4%) had stiffness that was felt to impair activity.

In the modified McBride group no MTP joint stiffness was noted by the patient in 10 feet (62%) and noticeable stiffness that was not bothersome was reported for the remaining feet (38%).

Overall Satisfaction

When asked if they would consider having bunion surgery again, 28 patients (88%) in the Chevron group said yes, four patients (12%) said no. In the modified McBride group, nine patients (90%) stated they would have the surgery again and one patient (10%) stated he would not have the surgery again.

OBJECTIVE RESULTS

Pre- and postoperative X-rays were available for review in all patients. Standing pre- and postoperative X-rays were available for 16 patients (50%) in the Chevron group and four patients (40%) in the McBride group. All remaining patients had at least one nonstanding X-ray that was used for pre- or postoperative evaluation.

Statistically significant differences between the Chevron and modified McBride groups were found in the following areas:

Intermetatarsal Angle Correction

The pre- and postoperative IM 1-2 angles are shown in Table 2. There is no significant difference in the preoperative angles, indicating the severity of the deformity in the two groups is similar. However, the difference in the amount of correction between the two groups is highly statistically significant ($P = 0.001$) with the Chevron osteotomy yielding a greater degree of correction. When multivariate statistical adjustments were made for the known differences between the two groups in age, length of followup, and number of additional procedures, the difference in the amount of correction in the IM 1-2 angle between the two groups remained statistically significant. Therefore, the Chevron procedure resulted in a greater correction of the hallux valgus deformity than the modified McBride procedure.

MTP Angle Correction

The pre- and postoperative MTP-1 angles are shown in Table 2. The P value of 0.50 indicates there is a borderline statistically significant difference in the preoperative MTP-1 angles between the groups. Postoperatively, the Chevron procedure achieved 10.1° of MTP correction compared to 7.8° of correction with the modified McBride (a statistically insignificant difference of 2.3° , $P = 0.210$). However, when multivariate statistical adjustments are made for differences between the two groups in age, length of follow up and the number of additional procedures, the difference in the amount of MTP-1 correction between the McBride and Chevron becomes statistically significant showing greater MTP correction with the Chevron procedure. After adjustment, the Chevron procedure resulted in greater MTP-1 angle correction than the McBride procedure by a mean of 5.7° ($P = 0.025$).

No statistically significant differences were found between the Chevron and modified McBride groups using any of the following objective criteria:

Tibial Sesamoid Position

The degree of displacement of the first metatarsal head in relation to the tibial sesamoid was measured on a scale of 0 to 3 based on the relationship of the tibial sesamoid to a line drawn down the midlongitudinal axis of the first metatarsal shaft.¹⁴ Using this scale, a position of 0 is normal and the tibial sesamoid in position 3 is subluxed greater than one-half of its width across the metatarsal axis. In the Chevron group, preoperative tibial sesamoid position averaged 1.4 (range 0-2) and postoperatively averaged 1.0 (range 0-3) for an average correction of 0.4 (in other words, an improvement of less than one grade). In the modified McBride group,

TABLE 2
Objective Results

	Chevron Osteotomy				Modified McBride			
	Preoperative	Postoperative	Postoperative (range)	Mean total correction	Preoperative	Postoperative	Postoperative (range)	Mean total correction
IM 1-2 angle (mean)	11.0°	6.5°	2-13°	4.5°	11.3°	10.5°	6-18°	0.8°
MTP-1 angle (mean)	21.2°	11.1°	0-32°	10.1°	24.8°	17.1°	7-30°	7.8°
Tibial sesamoid position (0,1,2,3) (mean)	1.4	1.0	—	0.4	1.6	1.2	—	0.4
Postoperative PROM (mean)								
Dorsiflexion	NA	44°	—	—	NA	49°	—	—
Plantarflexion	NA	24°	—	—	NA	23°	—	—

IM 1-2 = intermetatarsal angle between first and second metatarsals, MTP-1 = metatarsophalangeal angle of great toe, PROM = passive range of motion, na = data not available.

tibial sesamoid position averaged 1.6 (range 0 to 2) preoperatively and 1.2 (range 0-3) postoperatively for an average correction of 0.4. Neither procedure improved tibial sesamoid position significantly and the difference between the two groups was not statistically significant ($P = 0.879$).

Metatarsophalangeal Subluxation

Lateral subluxation of the base of the proximal phalanx has been described as one of the components of the hallux valgus deformity. The amount of subluxation present pre- and postoperatively can be measured radiographically¹⁵ to give additional information on the amount of correction achieved by hallux valgus corrective surgery.

In the Chevron osteotomy group, lateral subluxation of the base of the proximal phalanx in relationship to the head of the first metatarsal was present preoperatively in 12 feet and postoperatively in only two feet with an overall improvement of 1.5 mm in the degree of lateral subluxation. In the modified McBride group, ten of 17 feet had lateral subluxation at the MTP joint preoperatively and in four feet postoperatively for an overall improvement of 0.5 mm.

However, postoperatively the base of the proximal phalanx was uncovered medially due to excessive medial eminence resection in five patients (seven feet) and in two of these patients by as much as one-fourth of the total width of the articular surface of the base of the proximal phalanx. Although this is a cause of potential incongruity of the MTP joint, no significant degenerative changes or adverse effects were noted in these patients. However, longer term followup will be necessary. No patients following the modified McBride procedure had the base of the proximal phalanx uncovered by the first metatarsal head medially.

First Metatarsal Shortening

Shortening of the first metatarsal was determined by measuring the relative lengths of the first and second metatarsals pre- and postoperatively according to the method of Hardy and Clapham.⁵ In the Chevron group, the preoperative difference in the length of the first and second metatarsal had a mode of 0 mm (range -5 mm to +6 mm), indicating no difference in metatarsal length. Postoperatively, the mode of the difference was -2 mm (range, -9 mm to +2 mm) indicating an overall shortening of 2 mm of the first metatarsal.

In the modified McBride group the preoperative difference in first and second metatarsal length had a mode of 3 mm (range, -2 mm to +8 mm) and postoperatively of 4 mm (range, 0 mm to +9 mm) indicating an overall lengthening of the first metatarsal by 1 mm according to our data. Since no metatarsal osteotomy was performed, the apparent lengthening of the first metatarsal in relation to the second is probably due to differences in radiographic technique and standard error in measurement. There is no significant difference between the two procedures in the amount of shortening of the first metatarsal.

Capsular Release With the Chevron Procedure

Nine patients (12 feet) underwent a lateral capsular release and adductor hallucis tenotomy as part of the Chevron osteotomy procedure. Six patients (eight feet) had the release performed through the medial incision. Three patients (four feet) had the release performed through a separate incision in the first web space.

Of these nine patients, eight (11 feet) were totally satisfied with pain relief, and one patient (one foot) considered the foot was better. Appearance of the foot was totally satisfactory in eight patients (11 feet) and better in one patient (1 foot). No patient had stiffness in the great toe that impaired activity and in only three feet was there any stiffness noted.

Average MTP joint passive range of motion in the feet that had capsular releases and adductor tenotomies showed an average dorsiflexion range of motion of 50° and plantarflexion range of motion of 23° . This is similar to the average passive range of motion of the remaining Chevron patients that did not have a capsular release and adductor tenotomy (Table 2).

Average improvement in IM 1-2 angle in the Chevron patients that had capsulotomies and tenotomies was 4.3° compared to a 4.7° average improvement in those without a soft tissue release, which is not significant.

Average improvement in MTP-1 angle in the capsular release patients was 10.8° compared with an 8.7° average improvement in those that did not have the capsular release and adductor tenotomy.

No functionally significant advantage was demonstrated in the correction of the IM 1-2 or MTP-1 angle or in postoperative range of motion when the lateral capsular release was added to the Chevron procedure in this group of patients.

COMPLICATIONS

Chevron Osteotomy

Radiographic changes within the first metatarsal head was exhibited in three patients (10%) that underwent a Chevron osteotomy. Two of these patients had changes in both operated feet and one patient had these changes in only one of her two operated feet.

The types of radiographic changes were varied. There was one foot with total head involvement by cysts with early osteoarthritis (Fig. 1), with subtotal involvement with early osteoarthritis, two feet had cystic changes, but no degenerative joint changes and one foot had apparent increased osteodensity of the first metatarsal head, but no cysts. None of these patients had a lateral capsular release and adductor tenotomy at the time of surgery. All of these patients also had preoperative IM 1-2 angles of less than or equal to 12° . The ages of the three patients were 45, 52, and 55 years old.

Malunion of the distal first metatarsal osteotomy was observed at follow-up in two patients (three feet) (6%). In all three feet the distal fragment tilted into valgus angulation of 10° to 35° in relation to the proximal metatarsal shaft fragment (Fig. 2). One additional patient (one foot) lost fixation of the distal metatarsal fragment at 2 weeks postoperatively when the fixation pin was removed. A closed reduction was performed and the osteotomy healed in proper alignment with a satisfactory clinical result. One of the patients (one foot) with a malunion and the one patient that required a closed reduction of the osteotomy at 2 weeks had a

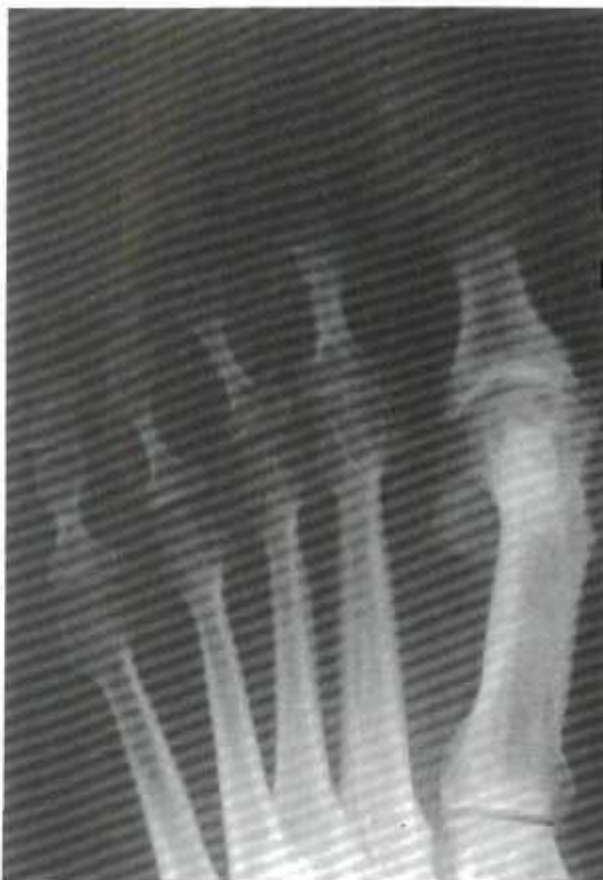

Fig. 1. Cystic changes noted in first metatarsal head following Chevron osteotomy.

lateral capsular release and an adductor tenotomy at the time of Chevron osteotomy.

Symptomatic decreased sensation and/or burning pain from neuromas of the sensory nerves to the great toe was observed in six patients, eight feet, (16%). Five patients (seven feet) had neuromas of the dorsal medial cutaneous nerve to the great toe in the area of the skin incision. One patient (one foot) had paresthesias in the first web space in the distribution of the deep peroneal nerve.

Five of the seven feet with dorsomedial cutaneous neuromas were judged either totally satisfied or better in terms of pain relief at followup. One foot subsequently had a neurectomy of the dorsal cutaneous nerve with good relief in pain, however, for the purposes of this study, was considered an unsatisfactory result. One foot was judged a poor result because of significant burning pain over the medial eminence of the first metatarsal head and also had a recurrence of hallux valgus that was deemed worse than the pain and deformity that was present preoperatively.

One patient, age 52, developed early osteoarthritis of the first MTP joint with narrowing of the joint space

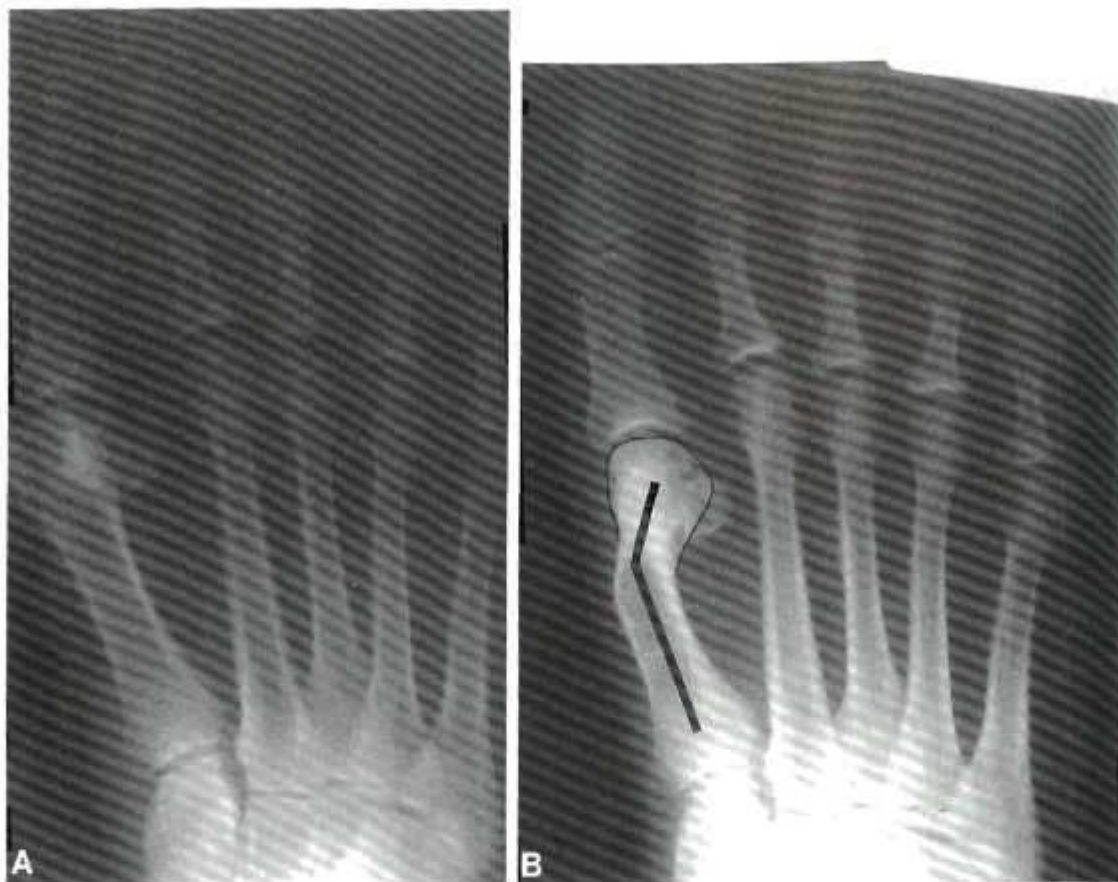

Fig. 2. A, Preoperative anteroposterior radiograph of Chevron osteotomy. B, Postoperative anteroposterior radiograph demonstrating valgus malunion of Chevron osteotomy. This patient also had a lateral capsule and adductor release.

and marginal osteophytes in one foot, but was totally satisfied with her result and had good toe range of motion with dorsiflexion of 30° and plantarflexion of 15°.

Modified McBride Procedure

Complications following the modified McBride procedure consisted of a neuropathy of the medial hallucal nerve in one patient (one foot) and of the deep peroneal nerve in the first web space bilaterally in one patient (two feet) for an overall neurologic complication rate of 14%. Both patients judged their overall results as better and stated they would have the surgery again. There was no radiographic evidence of osteoarthritis or avascular necrosis following the modified McBride procedure.

DISCUSSION

The validity of any comparison between the postoperative or outcome variables of these two groups is directly dependent upon how closely their preoperative characteristics are matched. Table 3 summarizes the

TABLE 3
Comparison of Study Group Characteristics

Variable	Chevron	McBride	P ^a
Number of patients	32	10	
Mean age (years)	44 (27-54)	35	0.002 ^b
Length of F/U (months)	25	38	0.019 ^a
Additional procedures per foot	1.1	0.6	0.028 ^a
IM 1-2 angle	11.0°	11.3°	0.672
MTP angle	21.2°	24.8°	0.050 ^a

* 95-99% confidence level.

^b 99% or greater confidence level.

comparison of the preoperative characteristics between the Chevron osteotomy and Modified McBride groups. As evidenced by the P^a values listed, all the preoperative variables between the two groups were statistically different except for the IM-2 angle. In addition, the Chevron procedures were all performed by one surgeon (D.E.B.) and the modified McBride procedures by another surgeon (T.O.C). Despite these possible sources of bias, this comparison of the two bunion procedures is worthwhile. When possible, these differences between the two groups was taken into account statisti-

ally through the use of multivariate regression adjustment.

In this comparison study the only statistically significant differences between the two procedures were in the amount of correction obtained. IM 1-2 and the MTP-1 angle were both improved significantly more with the Chevron osteotomy procedure than the modified McBride procedure without proximal osteotomy.

The Chevron osteotomy resulted in a greater improvement in the IM 1-2 angle with an average of 4.5° as compared to an average improvement of 0.8° for the modified McBride group. Average correction of the IM 1-2 angle in the Chevron group is similar to that reported by other authors which ranges from 2.3° to 7° .^{2,8,14} Correction of the IM 1-2 angle by the modified McBride procedure has been reported to average 5.2° to 6.1° of correction.^{11,13} However, a fibular sesamoidectomy was also performed in those patients.

This difference in correction of the IM 1-2 angle between the two groups was not influenced by the method of measurement of the IM 1-2 angle since the same method was used for measuring radiographs for both the Chevron osteotomy and the modified McBride patients.

All other variables that were studied did not prove to be significantly different between the groups. The insignificant variables included the objective measurements of tibial sesamoid position, MTP subluxation and first metatarsal shortening as well as the subjective measurements of pain relief, cosmetic results, and MTP joint mobility.

Both the Chevron osteotomy group and the modified McBride bunionectomy yielded satisfactory (totally satisfied or improved) overall subjective results in 92% and 88% of feet, respectively. Both groups of patients were also highly satisfied with the appearance of their feet following surgery.

Eighty-eight percent of Chevron patients and 90% of modified McBride patients stated they would have the procedure again, indicating a high level of satisfaction with both procedures.

These results compare favorably with those previously reported in the literature. Good or excellent results with the Chevron osteotomy had been reported by Meier and Kenzora in 89% of patients,¹⁴ by Hatstrup and Johnson in 92% of patients⁶ and by Boyd and Barron² in 93% of patients. Unpublished data by Mann and Pfeffinger have shown a 92% good or excellent result following the modified McBride procedure.¹³

There were three patients, five feet (10%) that had abnormal radiographic changes (cysts or increased osteodensity) in the first metatarsal head at follow-up. One patient (two feet) had no improvement in preoperative pain on one foot and satisfactory pain relief in

the other foot. One patient (one foot) had worse pain postoperatively. Both patients stated they would not have the procedure again. One additional patient (two feet) was totally satisfied despite these radiographic changes. Only one of the three patients with radiographic change had MTP joint stiffness that was bothersome. No patient that had a lateral capsular release and adductor tenotomy developed cystic changes in the first metatarsal head.

The etiology or predisposing factors for these cystic changes in the Chevron patients is unclear and does not appear to be associated with a lateral capsular release and adductor tenotomy as has been suggested by Meier and Kenzora.¹⁴ Whether the cystic changes in the metatarsal heads represented avascular necrosis (AVN) was not determined by this study. These changes were not labeled avascular necrosis because: (1) cystic changes alone are not enough to prove AVN, (2) no fragmentation or collapse occurred typical of AVN, and (3) some of the changes developed on both sides of the joint. More study to include bone biopsy or magnetic resonance imaging is needed to determine the etiology of the cystic changes. As reported by others, cystic changes of the distal first metatarsal does not appear to be incompatible with a satisfactory result.^{7,14}

None of the nine patients (12 feet) that had a lateral capsular and adductor release as part of the Chevron osteotomy procedure developed cystic changes in the first metatarsal head. However, one patient's osteotomy (one foot) healed in a malunited position and one patient (one foot) lost position at 2 weeks postoperatively, but had a successful closed reduction and healed satisfactorily. There was no statistically significant difference in MTP joint range of motion or correction of MTP-1 and IM 1-2 angles between the nine patients that had capsular releases and those that had Chevron osteotomy without capsular release. This lack of difference in correction with or without capsular release questions the need for performing this as part of the Chevron procedure, especially in view of the potential destabilizing effect it may have on the osteotomy.

Malunions occurred in two additional feet that did not have a capsular release. In these feet an excessive amount of medial eminence had been removed leaving a relatively small surface area for bony contact between the proximal and distal fragments. This may have contributed to the loss of alignment during the postoperative period.

When a lateral capsulotomy and adductor tenotomy are performed in addition to the Chevron osteotomy, this may have the effect of destabilizing the distal fragment of the first metatarsal (Fig. 3). We hypothesize that as the toe is brought into slight varus overcorrec-

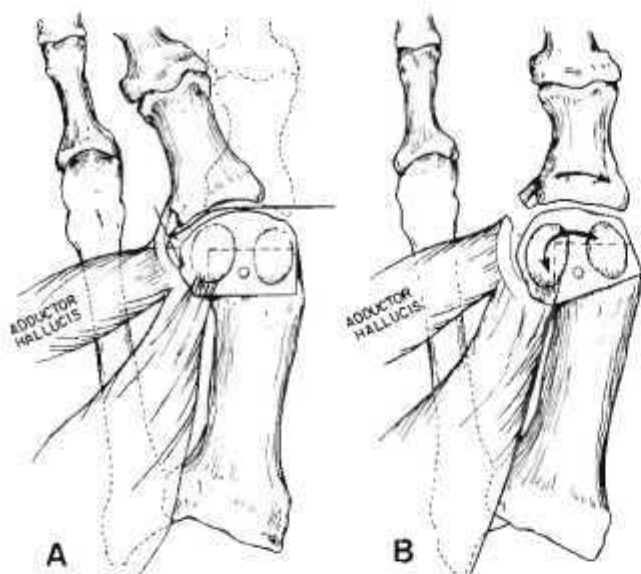


Fig. 3. A, Intra-articular lateral capsule and adductor release. B, Hypothesized mechanism for etiology of valgus malunion of Chevron osteotomy.

tion to relieve the stress on the medial capsular repair, a valgus rotatory moment is placed on the distal metatarsal head fragment by the base of the proximal phalanx. When the surface area for contact is sufficiently small from either excessive lateral displacement of the metatarsal head fragment or excessive resection of the medial eminence, the force against the metatarsal head may push it into valgus malalignment. Even a single K-wire, often used for fixation, may not adequately resist this, allowing rotation of the head about the pin and resulting in valgus angulation at the osteotomy site.

Both the modified McBride and Chevron osteotomy procedures were associated with postoperative neurological complications which have also been described by others following bunion surgery.¹⁻¹⁰ These resulted either from a direct injury to the medial cutaneous nerve about the hallux, most commonly at the proximal end of the medial incision, or from secondary nerve entrapment. These occurred despite a straight medial incision. There was also one case of injury to the deep peroneal nerve in each group. The Chevron osteotomy patient with deep peroneal nerve injury had also had an intra-articular lateral capsulotomy and adductor release pointing out a potential problem in performing this adjunctive procedure.

CONCLUSIONS

For the mild to moderate hallux valgus deformity, the Chevron osteotomy and the DuVries' modification of the McBride procedure without proximal metatarsal

osteotomy both gave similar satisfactory results in this series. The Chevron osteotomy resulted in a greater correction in both the IM 1-2 angle and the MTP-1 angle than the modified McBride procedure. The Chevron osteotomy was associated with postoperative cystic changes or increased osteodensity changes in the head of the first metatarsal (10%) and malunion (6%). Despite experienced surgeons and careful attention to the surgical technique, a 14% to 16% neurological complication rate was noted in both procedures. Lateral capsular release with the Chevron osteotomy was not associated with the development of cystic changes of the metatarsal head in this group of patients. Lateral release also did not improve the amount of correction of the hallux valgus deformity, and it may be a contributing factor to instability at the osteotomy site leading to a valgus malunion.

REFERENCES

- Alexander, I.J., and Johnson, K.A.: Injuries to the medial hallux nerve presented at AOFAS Meeting, July 1987.
- Boyd, B.M., and Barron, J.L.: A comparative study of the Chevron Mitchell osteotomies. Presented at the American Foot and Ankle Society Meeting, Atlanta, GA, February 7, 1988.
- Corless, J.R.: A Modification of the Mitchell Procedure (abstract). *J. Bone Joint Surg.*, 58B:138, 1976.
- DuVries, H.L.; In: *Surgery of the Foot*. St. Louis. C.V. Mosby, 1959, p. 381.
- Hardy, R.H., and Clapham, J.C.R.: Observations on hallux valgus. *J. Bone Joint Surg.*, 33B:376-391, 1951.
- Hatrup, S.J., and Johnson, K.A.: Chevron osteotomy: analysis of factors in patient dissatisfaction. *Foot and Ankle*, 5(6):327-332, 1985.
- Horne, G., Tanzer, T., and Ford, M.: Chevron osteotomy for treatment of hallux valgus. *Clin. Orthop.*, 183:32-36, 1984.
- Johnson, K.A., Cofield, R.H., and Morrey, B.F.: Chevron Osteotomy for Hallux Valgus. *Clin. Orthop.*, 142:44-47, 1979.
- Kahn, H.A.: Adjustment using multiple linear regression and multiple logistic functions. In: *An Introduction to Epidemiologic Methods*, New York, Oxford university Press, 1983, pp. 100-120.
- Kenzora, J.E.: Symptomatic incisional neuromas on the dorsum of the foot. *Foot Ankle*, 5(1):2-15, 1984.
- Mann, R.A., and Coughlin, M.J.: Hallux valgus—Etiology, Anatomy, Treatment and Surgical Considerations. *Clin. Orthop.*, 157:31-41, 1981.
- Mann, R.A., and Coughlin, M.J.: Hallux valgus and complications of hallux valgus. In: *Surgery of the Foot*, 5th Ed. Mann, R.A. (ed) St. Louis, C.V. Mosby, 1986, p. 86-98.
- Mann, R.A., and Pftfingler, L.: Hallux valgus: a critical review of the DuVries' modification of the McBride procedure personal communication.
- Meier, P.J., and Kenzora, J.E.: The Risks and Benefits of Distal First Metatarsal Osteotomies. *Foot Ankle*, 6(1):7-17, 1985.
- Smith, R.W., Reynolds, J.C., and Steward, M.J.: Hallux Valgus Assessment: Report of Research Committee of the American Orthopaedic Foot and Ankle Society. *Foot Ankle*, 5(2):92-103, 1984.

ABSTRACT
Eighty patients were treated with plaster casts. The criteria for an anteroposterior radiograph of the ankle show one percent of patients re-ports early difference in symmetry or instability after 1 year post-operation and in 9% of ligamentous early mobilization however, significant immobilization.

INTRODUCTION

The best ligaments treated of total mobility mobilization and residual symptoms patients' than in the or primary We want approach

* Dept. To whom 36, st. tv. † Dept. Denmark.